

# Oral Furosemide Therapy in Patients with Exudative Retinal Detachment Due to Hypertensive Retinopathy-IV

*by* Habibah Muhiddin

---

**Submission date:** 01-May-2021 10:11AM (UTC+0700)

**Submission ID:** 1575043645

**File name:** ative\_Retinal\_Detachment\_Due\_to\_Hypertensive\_Retinopathy-IV1.pdf (571.57K)

**Word count:** 2150

**Character count:** 12395

## Oral Furosemide Therapy in Patients with Exudative Retinal Detachment Due to Hypertensive Retinopathy-IV

Ichsan AM<sup>1,2\*</sup>, Stevanie N<sup>1</sup>,  
Habibah SM<sup>1,2</sup> and Budu P<sup>1,2</sup>

- 1 Faculty of Medicine, Department of Ophthalmology, Hasanuddin University, Makassar, Indonesia
- 2 Celebes Eye Center ORBITA, Makassar, Indonesia

**\*Corresponding author:**

Ichsan AM

✉ am\_ichsan@yahoo.com

Faculty of Medicine, Department of Ophthalmology, Hasanuddin University, Makassar, Indonesia.

Tel: +6281342280880

**Citation:** Ichsan AM, Stevanie N, Habibah SM, Budu P(2018) Oral Furosemide Therapy in Patients with Exudative Retinal Detachment Due to Hypertensive Retinopathy-IV. Ann Clin Lab Res. Vol.6 No.2: 240

### Abstract

**Introduction:** Hypertensive retinopathy is a condition characterized by a spectrum of retinal vascular signs in people with elevated blood pressure. This condition can be accompanied by exudative retinal detachment in hypertensive retinopathy grade IV. Furosemide is considered as a diuretic agent to force fluid absorption across the retinal epithelium. This is consistent with a model for ion transport in the isolated RPE, in which active furosemide-inhibitable transport of chloride from retina to choroid for a significant fraction of the short-circuit current.

**Objectives:** To report the efficacy of oral furosemide in patients with exudative retinal detachment due to hypertensive retinopathy-IV.

**Case presentation:** We reported two young patients, first patient with chronic kidney disease complained with decreased of visual acuity to 20/100 in the right and 20/200 in the left eye. The second patient with preeclampsia suddenly experienced bilateral visual loss to count finger on both eyes. Those patients showed sub-retinal fluid, macular star and cotton wool spots in both retina. Macular edema was seen by optical coherence tomography (OCT) examination in both eyes. Both cases were diagnosed as hypertensive retinopathy grade IV with exudative retinal detachment. Oral furosemide 40 mg once a day was given. On the first patient visual acuity improve to 20/80 on both eyes and on the second patient visual acuity improve to 20/400 on both eyes. Ocular ultrasonography (USG) examination showed significant decrease of exudative retinal detachment with in the 17 days.

**Conclusion:** Furosemide is diuretic agent and might be effective in resolution of exudative retinal detachment followed by improvement of visual acuities in patient with hypertensive retinopathy grade IV.

**Keywords:** Hypertension retinopathy; Exudative retinal detachment; Furosemide

**Received:** June 11, 2018; **Accepted:** July 07, 2018; **Published:** July 12, 2018

### Introduction

Hypertension is a significant risk factor for heart disease, kidney disease, ischemic and hemorrhagic stroke, that may cause sudden death. In the field of eye diseases, severe hypertension accompanied by the presence of retinal hemorrhages, exudates and papil edema may cause blindness and very poor prognosis if it delayed for treatment [1].

Preeclampsia is characterized by new onset hypertension and proteinuria in pregnancy. Placental ischemia led to activation of the maternal vascular endothelium elevates vascular sensitivity

to angiotensin II, and decrease formation of vasodilators such as nitric oxide. These endothelial abnormalities cause generalized vasoconstriction throughout the body including kidney [2]. Patients with chronic kidney disease, impaired renal sodium handling leads hypertension because of extracellular fluid volume increases despite a decreased of total peripheral resistance [3].

The typical sign of hypertensive retinopathy is retinal vascular changes in hypertensive person. Initially there is vasoconstrictive stage. This stage is seen as a generalized narrowing of the retinal arterioles, intimal thickening, hyperplasia of the media wall, and hyaline degeneration in the subsequent, sclerotic. The next

stage is an exudative stage. It is signed by disruption of the blood retinal barrier, necrosis of the smooth muscles and endothelial cells, exudation of blood and lipids, and retinal ischemia. These changes are seen as microaneurysms, hemorrhages, hard exudates and cotton-wool spots. Swelling of the optic disk usually indicates severe hypertension [4].

Furosemide inhibits chloride transport systems in a wide variety of epithelia. Furosemide-inhibitable chloride (Cl) absorption may be a driving force for fluid absorption across the retinal pigment epithelium (RPE). This is consistent with a model for ion transport in the isolated RPE, in which active furosemide-inhibitable transport of chloride from retina to choroid accounts for a significant fraction of the short-circuit current [5]. The RPE pump absorbs and drains fluid from the retinal to the choroidal surface [6]. The flow of subretinal fluids may assist the sensory retina in attachment to the RPE, and unconventional routes for aqueous humor drainage in eyes with retinal detachments [6].

In this article, we report cases of 2 young patients with exudative retinal detachment due to hypertensive retinopathy grade-IV who led to the diagnosis and management of hypertensive retinopathy with oral furosemide.

## Case Presentation

### Case 1

A 21-year-old male patient complained a sudden blurred of vision in both eyes. Patient has a history of hypertension and kidney failure since two months ago and routine dialysis for twice a week. Initial ophthalmology assessment revealed visual acuity on the right eye was 20/100 and the left eye was 20/200. Anterior segment examination showed subconjunctival bleeding in the right eye. Posterior segment examination revealed hard exudates, macular star and inferior retinal detachment in both eyes with remarkably visible a shifting fluid. Patient received citicholine 1000 mg, furosemide, amlodipine 10 mg, bisoprolol, and valsartan once daily, domperidon 3 times daily, methylprednisolone eye drops combined with sodium diclofenac eye drops 5 times daily in both eyes (Figure 1).

Seventeen days after oral therapy with furosemide, visual acuity increased to 20/80 in both eyes. Anterior segment showed diminished of sub-conjunctival bleeding in the right eye. Posterior segment examination revealed cotton wool spots and shallow detachment at the inferior retina in both eyes (Figures 2 and 3).

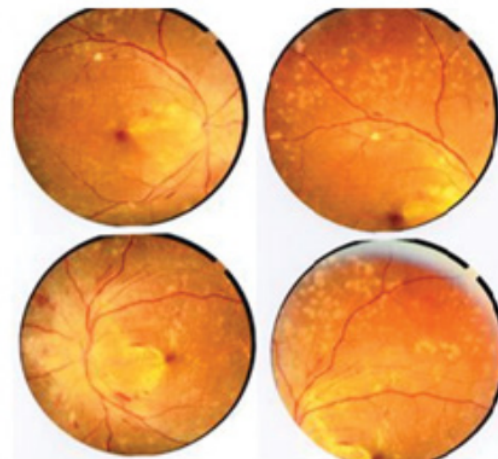
### Case 2

A 26-year-old woman complained a sudden blurred of vision in both eyes, one day after delivered her second child. Antenatal care recorded hypertension history including anti-hypertensive agent therapy. After delivered, her blood pressure increased to 180/100 mmHg and patient was immediately transferred to district hospital. Ophthalmology examination showed visual acuity in both eyes was 2/60. Anterior segment was within normal limit, while some abnormalities in posterior segment were found such as hyperemia of the optic nerve head (ONH), cotton-wool spots, and inferior retinal detachment that changed according to changing position. Patient received oral citicholine 1000 mg, and

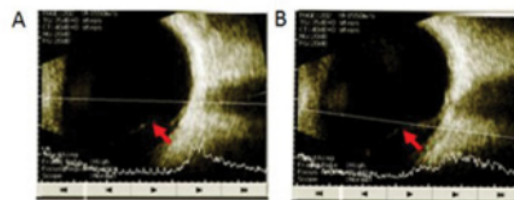
furosemide 40 mg, amlodipine 10 mg, and Isosorbide dinitrate 5 mg once daily, hepatoprotector twice daily, methylprednisolone eye drops and sodium diclofenac eye drops 3 times daily in both eyes (Figures 4-6). Ten days after treated by oral furosemide, visual acuity improved to 20/400 in both eyes. Anterior segment remain normal and decreased of exudate sub-retinal in inferior quadrant (Figures 7 and 8).

## Discussion

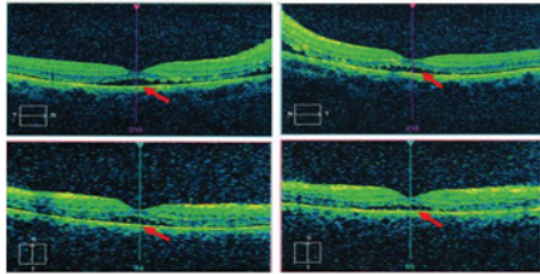
High level of blood pressure affects precapillary arterioles and capillaries, the anatomical loci of autoregulation and nonperfusion [7] which is may cause blood-retina barrier breakdown or arteriole spasm and occlusion of capillaries [8]. This condition resulted intraretinal hemorrhages, cotton-wool spots, retinal edema, or swelling of the optic disc [8]. The effects of arterial hypertension can



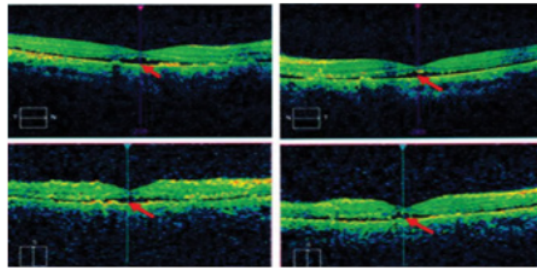
**Figure 1** Redness of the optic nerve head with blurred disc margin, presence of macular star, and cotton wool spots, flame shaped hemorrhages, and exudative retinal detachment.



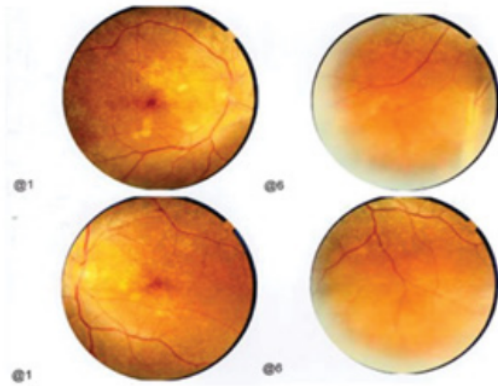
**Figure 2** Ultrasound of A: Right eye, B: Left eye. Normal echo, clear lens and vitreus, red arrow indicated exudative retinal detachment, while choroid, sclera and optic nerve were intact.



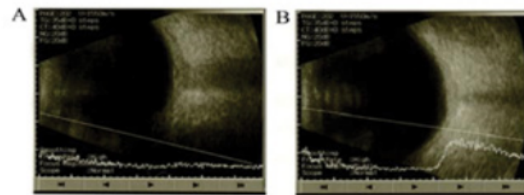
**Figure 3** OCT findings were normal of foveal depression, but visible subretinal fluid indicated by arrow.



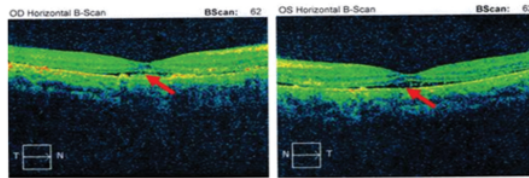
**Figure 6** OCT of the second patient was similar with first patient's OCT included the presence of subretinal fluid which is indicated by red arrow.



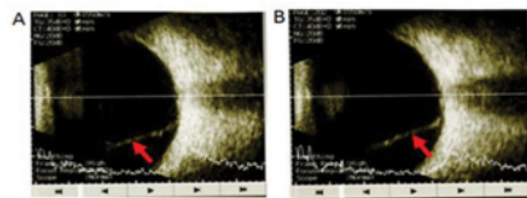
**Figure 4** Peripapillary margin was blurred, macular star, and cotton wool spots were found and exudative detachment in the inferior retina.



**Figure 7** Ocular ultrasound at the day-10 revealed diminished of exudative detachment.



**Figure 8** The 10<sup>th</sup> day of OCT of the second patient showed decreased of sub-retinal fluid.



**Figure 5** Ultrasound of A: Right eye, B: Left eye. Lens and vitreous were clear, exudative retinal detachment was shown by red arrows, while choroid, sclera and optic nerve were intact.

be directly visualized in the fundus [9]. These changes may involve the retinal arterioles, the choroid, and the optic nerve [9]. Hypertensive retinopathy graded into a vasoconstrictive phase, an exudative phase, a sclerotic phase, and complications of the sclerotic phase. In the vasoconstrictive phase, the rise of systemic blood pressure excites pliable and nonsclerotic retinal

vessels to increase their vascular tone by autoregulation [10]. In the exudative phase, blood is extravasated to form flame-shaped and splinter hemorrhages. Retinal capillary closure with areas of nonperfusion may be observed by fluorescein angiography. Cotton-wool spots are seen scattered in the posterior pole. Breakdown of the blood-retinal barrier can be quantitated by vitreous fluorophotometry [10]. Metabolic transport activity of the RPE is the mechanism for dehydrating the subretinal space. It may be related to retinal adhesiveness [11,12]. Furosemide-inhibitable chloride (Cl) absorption may be a driving force for fluid absorption through the RPE [5,13,14]. Furosemide is effective at the apical side of the RPE that might cause delayed reabsorption of subretinal fluid following retinal detachment surgery [14]. It reduced the apical-to-basal Cl-flux and suppressed the net Cl-flux. The transepithelial electrical current was reduced. Furosemide had no effect when Cl was removed from the bathing medium. It shows that furosemide acts on a transport site needs extracellular Cl [15]. It was reported the usage of furosemide in patients with diabetic who had significant macular edema and visual loss,

the condition evolved favorably under treatment with gradual remission of macular edema and recovery of visual function for oral therapy with furosemide 40 mg daily for 3 weeks [16]. Patients with diabetic macular edema should be treated with oral furosemide 40 mg twice daily for 2 weeks to reduce the amount of fluid overload and resolving the macular edema [17].

## Conclusion

In summary, furosemide treatment is effective for patients with hypertensive retinopathy grade-IV with exudative retinal detachment, based on literature review and our cases. In cases of hypertension crisis, blood pressure should be aggressively controlled and gradually normalized the systemic condition and to achieve an improvement of visual acuity.

## References

- 1 Gabb GM, Mangoni AA, Anderson C, Arnolda L, Cowley D, et al. (2016) Guidelines for the diagnosis and management of hypertension in adults. National Heart Foundation of Australia. 1-84.
- 2 Palei AC, Spradley FT, Warrington JP, George EM, Granger JP, et al. (2013) Pathophysiology of hypertension in preeclampsia: A lesson in integrative physiology. *Acta Physiol (Oxf)* 208(3): 224-233.
- 3 Abraham G, Arun KN, Gopalakrishnan N, Renuka S, Pahari DK, et al. (2017) Management of hypertension in chronic kidney disease: Consensus statement by an expert panel of Indian nephrologist. *J of the physic. of Ind (suppl)* pp. 6-22.
- 4 Wong TY, Mitchell P (2004) Hypertensive retinopathy. *N Engl J Med* 351: 2310-2317.
- 5 Frambach DA, Valentin JL, Weiter JJ (1989) Furosemide-sensitive Cl transport in bovine retinal pigment epithelium. *Invest Ophthalmol and Vis Sci* (30): 2271-2274.
- 6 Kita M, Michael F (1992) Effects on retinal adhesive force in vivo of metabolically active agents in the subretinal Space. *Invest Ophthalmol and Vis Sci* (33): 1883-1887.
- 7 Cantor LB, Rapuano CJ, Cioffi GA (2016) Retinal vascular diseases in : American Academy of Ophthalmology, Section 12. Retina and vitreous. pp.145-146.
- 8 Lang GK (2000) Degenerative retinal disorders In: *Ophthalmology A Short Text Book*. 3rd Ed Thieme. New York, USA. pp. 328-337.
- 9 Quillen D, Blodi B (2002) Clinical retina in American Medical Association. United States. 136-137.
- 10 Erden S, Bicakci E (2012) Hypertensive retinopathy: Incidence, risk factors and comorbidities. *Clin Exp Hypertens* 34(6): 397-401.
- 11 Henderson AD, Biousse V, Newman NJ, Lamirel C, Wright DW, et al. (2012) Grade III or Grade IV Hypertensive Retinopathy with Severely Elevated Blood Pressure. *West J Emerg Med*. 13(6): 529-534.
- 12 Tso MOM, Jampol LM (1982) Pathophysiology of hypertensive retinopathy. *J Ophthalmol* (89): 1132-1145.
- 13 Frambach DA, Misfeldt DS (1983) Furosemide-sensitive Cl transport in embryonic chicken retinal pigment epithelium. *Am J Physiol* pp.244-246.
- 14 DiMattio J, Degnan KJ, Zadunaisky JA (1983) A model for transepithelial transport across the isolated retinal pigment epithelium of the frog. *Exp Eye Res* (37): 409-420.
- 15 Tsuboi S, Pederson JE (1986) Experimental retinal detachment: Furosemide-inhibitable fluid absorption across retinal pigment epithelium *in vivo*. *Arch Ophthalmol* (104): 602-603.
- 16 Koo NK, Kim YC (2012) Resolution of macular edema after systemic treatment with furosemide. *Korean J Ophthalmol* 26(4): 312-315.
- 17 Ciardella AP (2004) Partial resolution of diabetic macular edema after systemic treatment with furosemide. *Br J Ophthalmol* (88): 1224-1229.

# Oral Furosemide Therapy in Patients with Exudative Retinal Detachment Due to Hypertensive Retinopathy-IV

## ORIGINALITY REPORT

**27%**  
SIMILARITY INDEX

**12%**  
INTERNET SOURCES

**25%**  
PUBLICATIONS

**7%**  
STUDENT PAPERS

## PRIMARY SOURCES

- 1** Tsuboi, Shunji. "Experimental Retinal Detachment : XI. Furosemide-Inhibitable Fluid Absorption Across Retinal Pigment Epithelium In Vivo", Archives of Ophthalmology, 1986.  
Publication **6%**
- 2** Mark O.M. Tso, Lee M. Jampol. "Pathophysiology of Hypertensive Retinopathy", Ophthalmology, 1982  
Publication **3%**
- 3** en.wikipedia.org  
Internet Source **2%**
- 4** T WONG. "The Eye in Hypertension", Comprehensive Hypertension, 2007  
Publication **2%**
- 5** bjo.bmj.com  
Internet Source **1%**
- 6** www.acmicrob.com  
Internet Source **1%**
- 7** Submitted to CSU, Long Beach  
Student Paper

1 %

8

link.springer.com

Internet Source

1 %

9

Naman R. Rao, Chandramani B. More, Rahi M. Brahmhatt, Youbai Chen, Wai-kit Ming.

"Causal inference and directed acyclic graph: An epidemiological concept much needed for oral submucous fibrosis", Journal of Oral Biology and Craniofacial Research, 2020

Publication

1 %

10

Q D Nguyen. "Bevacizumab suppresses choroidal neovascularisation caused by pathological myopia", British Journal of Ophthalmology, 2005

Publication

1 %

11

ALEXANDER E. MORGAN. "Presumed Malignant Plasmacytoma of the Choroid as the First Manifestation of Multiple Myeloma", Retina, 12/2003

Publication

1 %

12

Palei, A. C., F. T. Spradley, J. P. Warrington, E. M. George, and J. P. Granger.

"Pathophysiology of hypertension in pre-eclampsia: a lesson in integrative physiology", Acta Physiologica, 2013.

Publication

1 %

13	A H Alsuhaibani. "Confocal microscopy of the cornea in nephropathic cystinosis", British Journal of Ophthalmology, 2005 Publication	1 %
14	docshare.tips Internet Source	1 %
15	A P Ciardella. "Partial resolution of diabetic macular oedema after systemic treatment with furosemide", British Journal of Ophthalmology, 9/1/2004 Publication	<1 %
16	Tsuboi, Shunji. "Experimental Retinal Detachment : X. Effect of Acetazolamide on Vitreous Fluorescein Disappearance", Archives of Ophthalmology, 1985. Publication	<1 %
17	intl-content.nejm.org Internet Source	<1 %
18	"Diabetic Retinopathy", Springer Science and Business Media LLC, 2010 Publication	<1 %
19	"Encyclopedia of Ophthalmology", Springer Science and Business Media LLC, 2018 Publication	<1 %
20	J. L. Edelman, H. Lin, S. S. Miller. "Acidification stimulates chloride and fluid absorption across frog retinal pigment epithelium",	<1 %

21

Y. HOTTA. "Different mutation of the XLR51 gene causes juvenile retinoschisis with retinal white flecks", British Journal of Ophthalmology, 2001

Publication

---

<1 %

---

Exclude quotes      On

Exclude matches      < 5 words

Exclude bibliography      On